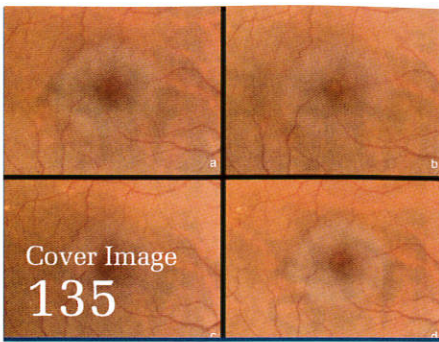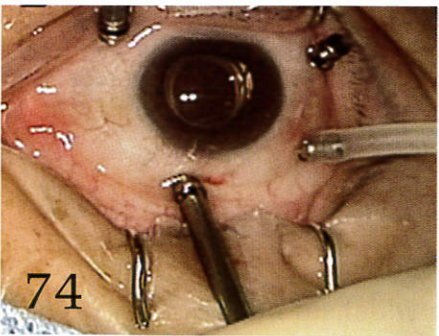
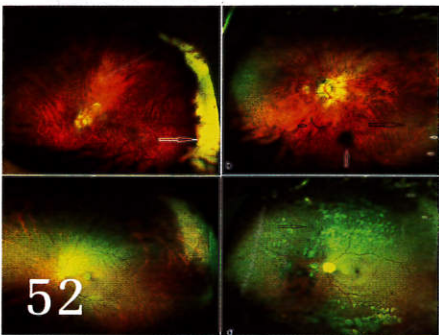
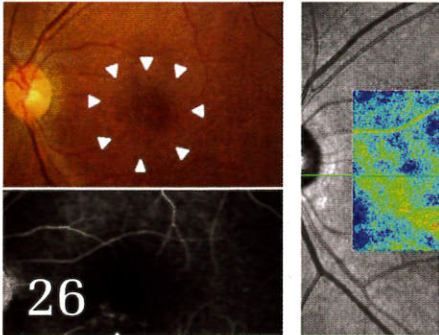


OSLI Retina

OPHTHALMIC SURGERY LASERS & IMAGING

Volume 46 • Number 1

JANUARY 2015



■ Practical Retina

Geographic Atrophy: Clinical Impact and Emerging Treatments 8
Hershel R. Patel, MS, MD; David Eichenbaum, MD

■ Eight Questions With Carmen Puliafito

Interview With Allen C. Ho, MD 148

■ Clinical Science

Optical Coherence Tomography Measurements of Choroidal Thickness in Healthy Eyes: Correlation With Age and Axial Length 18

Ashkan M. Abbey, MD; Ajay E. Kuriyan, MD, MS; Yasha S. Modi, MD; Mariana R. Thorell, MD; Renata P. Nunes, MD; Raquel Goldhardt, MD; Zohar Yehoshua, MD, MHA; Giovanni Gregori, PhD; William Feuer, MS; Philip J. Rosenfeld, MD, PhD

Choroidal Thickness and Choroidal Blood Flow After Intravitreal Bevacizumab Injection in Eyes With Central Serous Chorioretinopathy 25
Masahiro Okamoto, MD; Toyooki Matsuura, MD, PhD; Nahoko Ogata, MD, PhD

Choroidal Thickness in Macular Holes: A Case-Control Study 33
Lucy T. Xu, BS; Sunil K. Srivastava, MD; Justis P. Ehlers, MD; Peter K. Kaiser, MD

Retrospective Comparisons of Vitrectomy With and Without Air Tamponade to Repair Lamellar Macular Hole 38
Tatsuhiko Sato, MD, PhD; Kazuyuki Emi, MD, PhD; Hajime Bando, MD, PhD; Toshihide Ikeda, MD

Recovery of Photoreceptor Layer on Spectral-Domain Optical Coherence Tomography After Vitreous Surgery Combined With Air Tamponade in Chronic Idiopathic Macular Hole 44
Feng He, MD; Fangtian Dong, MD; Weihong Yu, MD; Rongping Dai, MD

Retina Evaluation With Nonmydriatic Ultrawide-Field Color Imaging After Cataract Extraction Surgeries in Asymptomatic Patients 50
Shulamit Schwartz, MD; Carmen Luz Gonzalez, MD; Ramanath Bhandari, MD; Scott N. Oliver, MD; Naresh Mandava, MD; Hugo Quiroz-Mercado, MD

Dexamethasone Intravitreal Implant for Pseudophakic Cystoid Macular Edema in Patients With Diabetes 56
Rahul N. Khurana, MD; James D. Palmer, MD; Travis C. Porco, PhD; Mark R. Wieland, MD

Cost Comparison of Intravitreal Aflibercept With Bevacizumab and Ranibizumab for the Treatment of Wet Age-Related Macular Degeneration 62
Adeel H. Shaikh, MD; Brian W. Toussaint, MD; Daniel M. Miller, MD; Michael R. Petersen, MD; Robert E. Foster, MD; Christopher D. Riemann, MD; Robert K. Hutchins, MD; Robert A. Sisk, MD

■ Experimental Science

Fluidics Comparison Between Dual Pneumatic and Spring Return High-Speed Vitrectomy Systems 68
Rodrigo A. Brant Fernandes, MD; Bruno Diniz, MD; Paulo Falabella, MD; Ramiro Ribeiro, MD; Anderson G. Teixeira, MD; Octaviano Magalhães Jr., MD; Nilva Moraes, MD; Andre Maia, MD; Michel E. Farah, MD; Mauricio Maia, MD; Mark S. Humayun, MD

■ Technique

Trimanual Technique Using Assistant-Controlled Light Probe Illumination and Wide-Angle Viewing System in 23-Gauge Sutureless Vitrectomy for Diabetic Tractional Retinal Detachment 73
Hoseok Moon, MD; Dae Yeong Lee, MD; Dong Heun Nam, MD, PhD

■ Case Reports

Visual Recovery and OCT Evolution Following Central Retinal Artery Occlusion Treated With Intra-arterial Verapamil and Alteplase Infusion 77
Jaclyn L. Kovach, MD; Brian Mason, MD

OSLI Retina

OPHTHALMIC SURGERY LASERS & IMAGING®

Volume 46 • Number 1

JANUARY 2015

Treatment of Cytomegalovirus Retinitis With Cytomegalovirus-Specific T-Lymphocyte Infusion 80
Mrinali Patel Gupta, MD; Peter Coombs, MD; Susan E. Prockop, MD; Aisha A. Hasan, MD; Ekatarina Doubrovina, MD, PhD; Richard J. O'Reilly, MD; Stuart H. Cohen, MD; Susanna S. Park, MD PhD; Szilárd Kiss, MD

Regression of Macular Drusenoid Retinal Pigment Epithelial Detachments After Plaque Radiation Therapy 84
Paul T. Finger, MD; Daniel Simhae, MD; Ekaterina Semenova, MD

Retinal Pigment Epithelial Tear After Intravitreal Aflibercept for Neovascular Age-Related Macular Degeneration 87
Taku Sato, MD; Sotaro Ooto, MD; Mihoko Suzuki, MD; Richard F. Spaide, MD

Intravitreal Injection of Ziv-Aflibercept in Patient With Refractory Age-Related Macular Degeneration 91
João Rafael de Oliveira Dias, MD; Camilla Oliveira Xavier, MD; André Maia, MD, PhD; Nilva Simeren Bueno de Moraes, MD, PhD; Carsten Meyer, MD, PhD; Michel Eid Farah, MD, PhD; Eduardo Büchele Rodrigues, MD, PhD

Bevacizumab in Macular Serous Detachments Associated With Waldenström's Macroglobulinemia 95
Kapil G. Kapoor, MD; Maxwell S. Wagner

Oral Rifampin for Central Serous Retinopathy: A Strategic Approach in Three Patients 98
Andrew E. Pouw, BA; Lisa C. Olmos de Koo, MD, MBA

Inner Segment Ellipsoid Layer Restoration After Macula-Off Rhegmatogenous Retinal Detachment 103
Jayanth Sridhar, MD; Harry W. Flynn Jr, MD; Yale Fisher, MD

Vitrectomy Without Gas Tamponade for Macular Retinoschisis Associated With Normal-Tension Glaucoma 107
Lukpan Orazbekov, MD; Tsutomu Yasukawa, MD, PhD; Yoshio Hirano, MD, PhD; Shuntaro Ogura, MD; Hideaki Usui, MD; Miho Nozaki, MD, PhD; Yuichiro Ogura, MD, PhD

Ghost Cell Glaucoma Following Sutureless Scleral-Fixated Posterior Chamber Intraocular Lens Placement 111
Jordan M. Thompson, MD; Jonathan S. Chang, MD; J. Antonio Bermudez-Magner, MD; Sander R. Dubovy, MD

Acute Macular Neuroretinopathy: A Case Report and Review of the Literature, 2002–2012 114
Hassan A. Aziz, MD; Wajiha J. Kheir, MD; Ryan C. Young, MD; Ryan F. Isom, MD; Sander R. Dubovy, MD

Natural Course of Symptomatic Focal Choroidal Excavation 125
Luisa Pierro, MD; Giuseppe Casalino, MD; Ugo Introini, MD; Marco Gagliardi, MD; Jessica Sergenti, MD; Maria Lucia Cascavilla, MD; Francesco Bandello, MD, FEBO

Stability of Macular Traction in Involuntional Diabetic Retinopathy Over a 5-Year Course 131
Daniel L. Chao, MD, PhD; Harry W. Flynn Jr., MD

A Novel Clinical Sign in Macular Telangiectasia Type 2 134
Animesh Jindal, MD; Himadri Choudhury, MS; Avinash Pathengay, FRCS; Harry W. Flynn Jr., MD

The Role of Intravitreal Trimethoprim/Sulfamethoxazole in the Treatment of Toxoplasma Retinochoroiditis 137
Himadri Choudhury, MS; Animesh Jindal, MD; Avinash Pathengay, FRCS; Abhishek Bawdekar, MS; Thomas Albin, MD; Harry W. Flynn Jr., MD

■ Perspectives in Retina

Paul Sullivan: Catalyst in the History and Use of Intraocular Sulfur Hexafluoride 141
Christopher F. Blodi, MD

