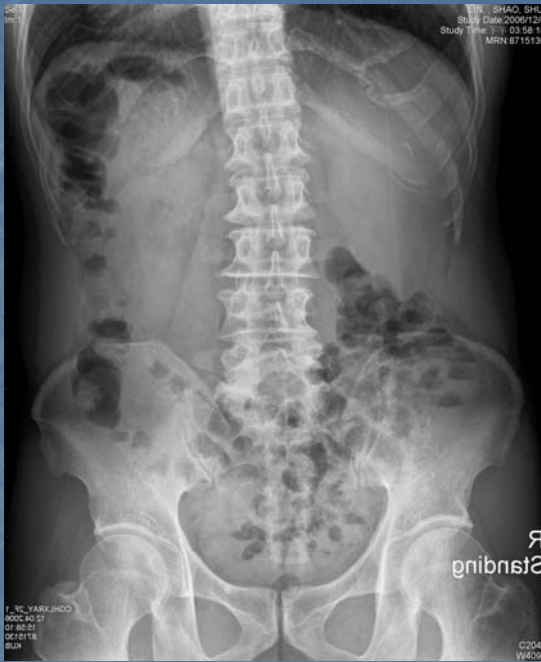

腰椎狹窄症

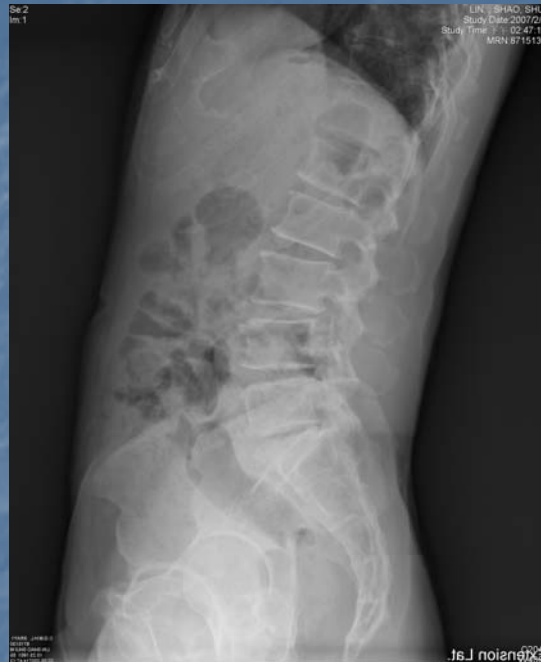
Lumbar Spinal Stenosis syndrome

手術圖譜

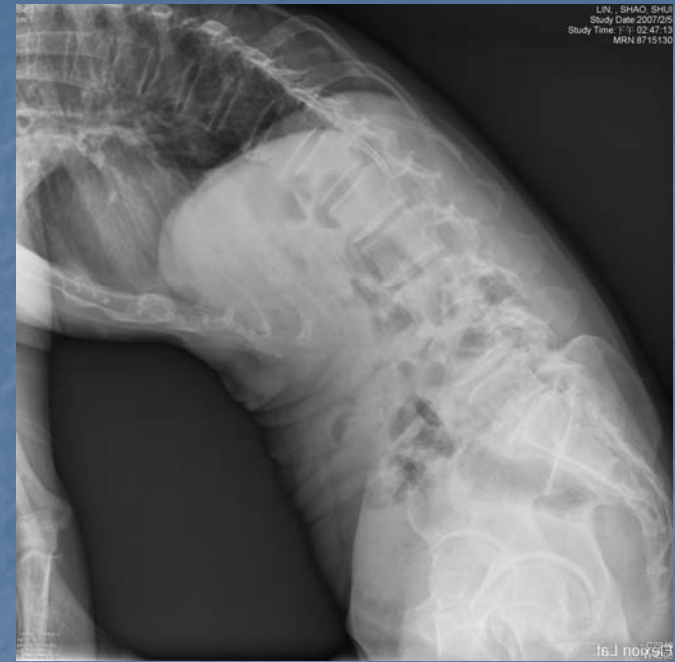骨科部脊椎科



KUB



Extension  
view



Flexion  
view

動態X光片 (dynamic view) 無明顯不穩定

# 間歇性跛行 Intermittent Claudication

	<b>Neurologic</b>	<b>Vascular</b>
<b>Disease</b>	Spinal stenosis	DM, vascular stenosis
<b>Pain</b>	Proximal to distal	Distal to proximal
<b>Bicycle</b>	OK	Poor
<b>Pulse</b>	Present	May be absent
<b>Skin</b>	Normal	Thin, shiny
<b>Relieved</b>	Sitting or bending	Sitting or standing

脊椎狹窄症常見之症狀：

下背痛(low back pain)、坐骨神經痛或腰腿痛(sciatica)、  
間歇性跛行(intermittent claudication)

# Lumbar Neurological Exam

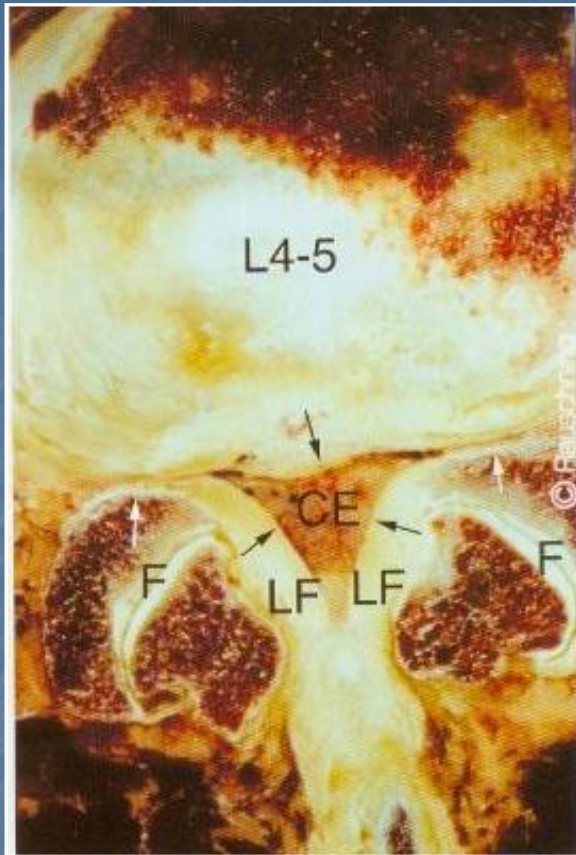
	L4	L5	S1
Motor	Tibialis anterior	EHL	FHL
Sensation	Medial lower leg, knee, big toe	Lateral lower leg, dorsal foot	Lateral foot
Reflex	Knee Jerk		Ankle Jerk

Straight leg raising test  
Faber's test  
Femoral stretch test

腰椎狹窄症的理學與神經學檢查

## Pathology of Lumbar Spinal Stenosis

- bulging disc
- facet joint hypertrophy
- ligamentum flavum hypertrophy

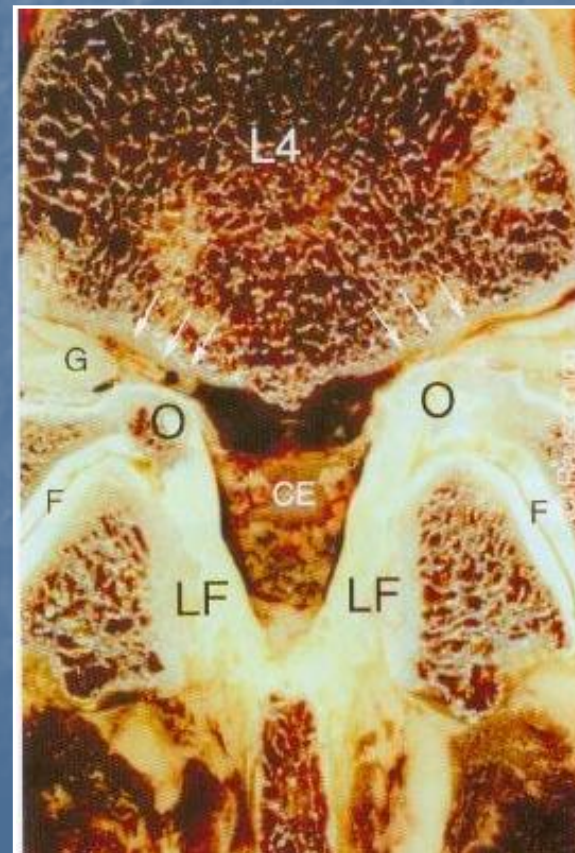


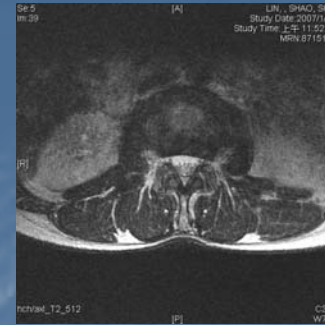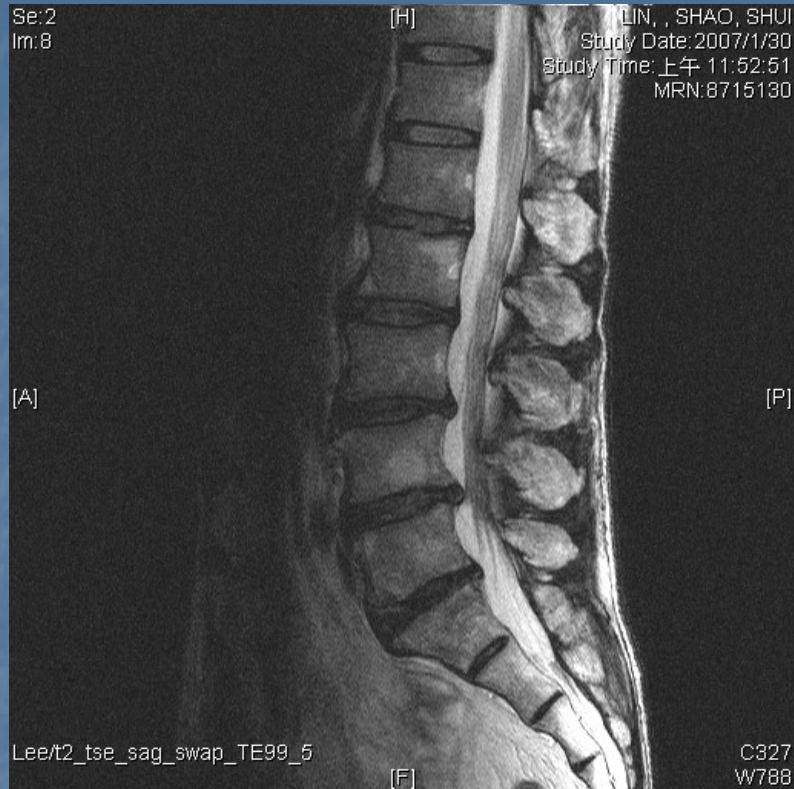
CE : cauda equina

F : facet joint

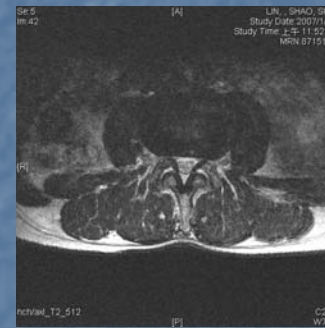
G : ganglion

LF : ligamentum flavum

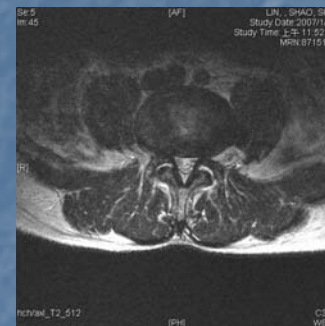




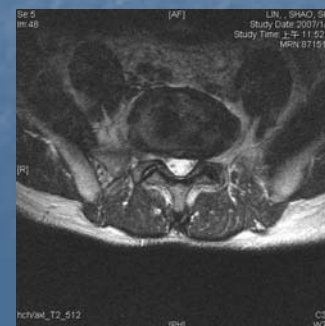L2-L3



L3-L4

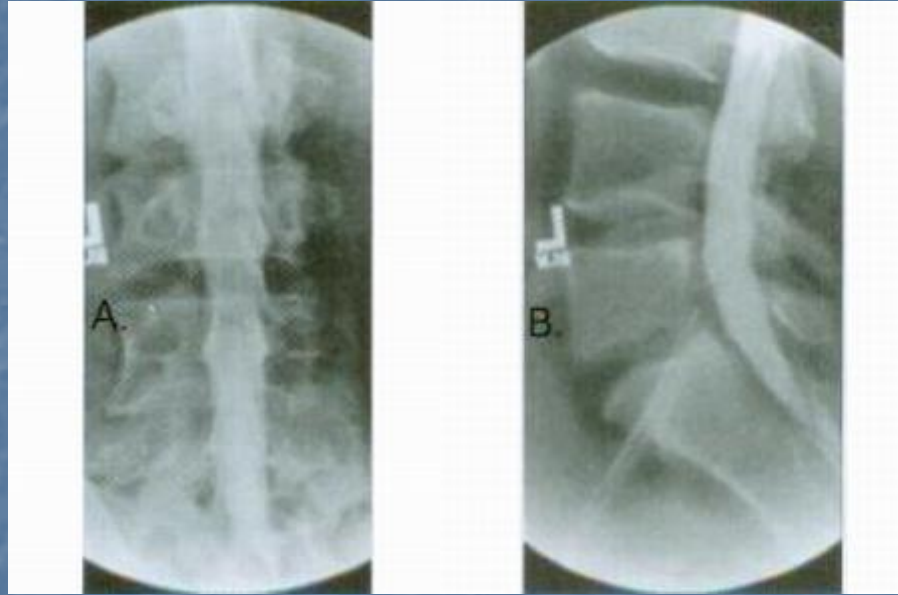


L4-L5

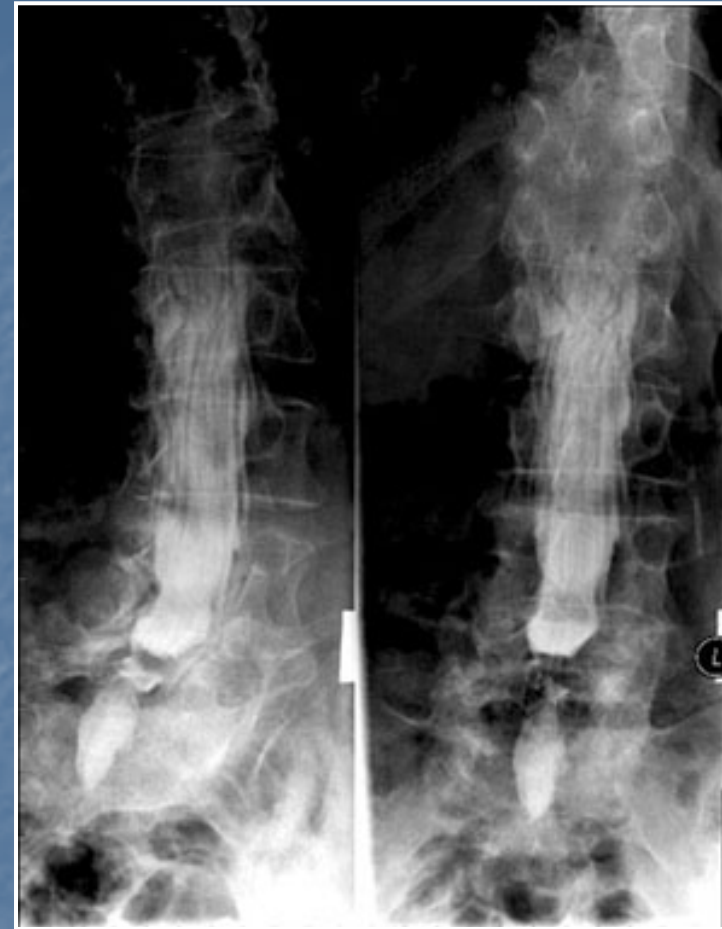

L5-S1

# 腰椎狹窄症之 MRI findings



正常



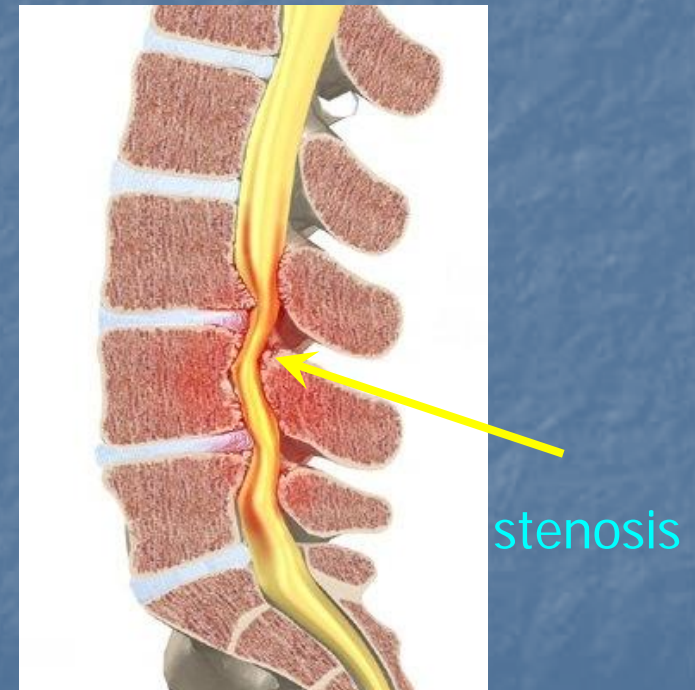
腰椎狹窄症

# 脊髓造影術 (Myelogram)

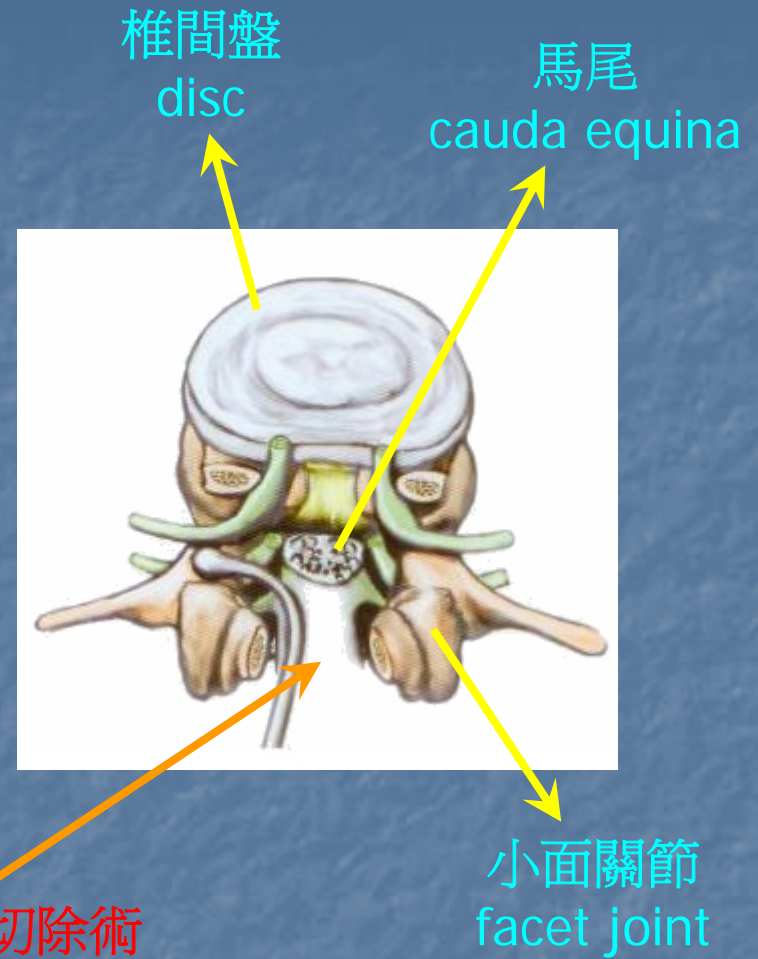
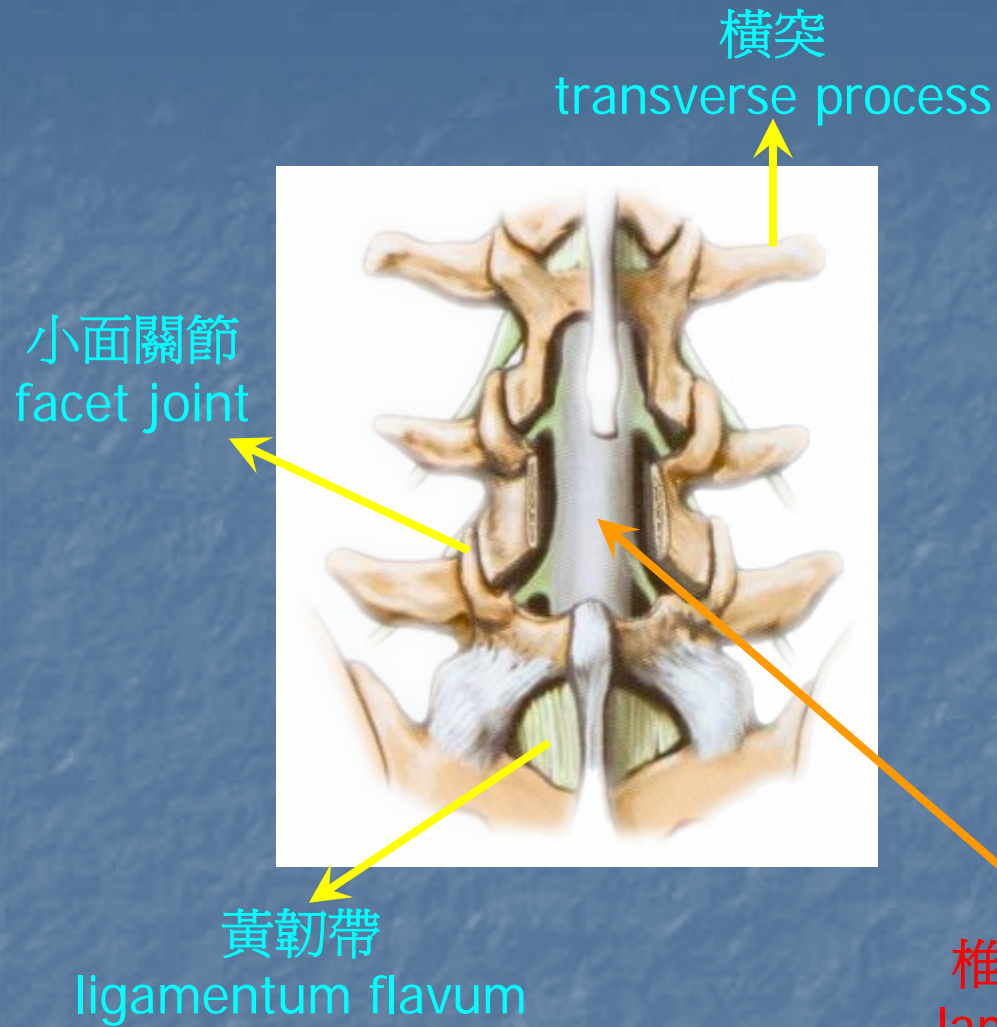
# 腰椎狹窄症手術種類

## Lumbar Spinal Stenosis Surgical Procedures

- 椎板切除術 Laminectomy
- 椎板開窗術 Laminotomy
- 單側椎板切除術 Unilateral hemilaminectomy
- 多孔椎板開窗術 Multiple laminotomy (hourglass compression at several levels)
- 椎板切除術+脊椎融合術 Laminectomy + Fusion







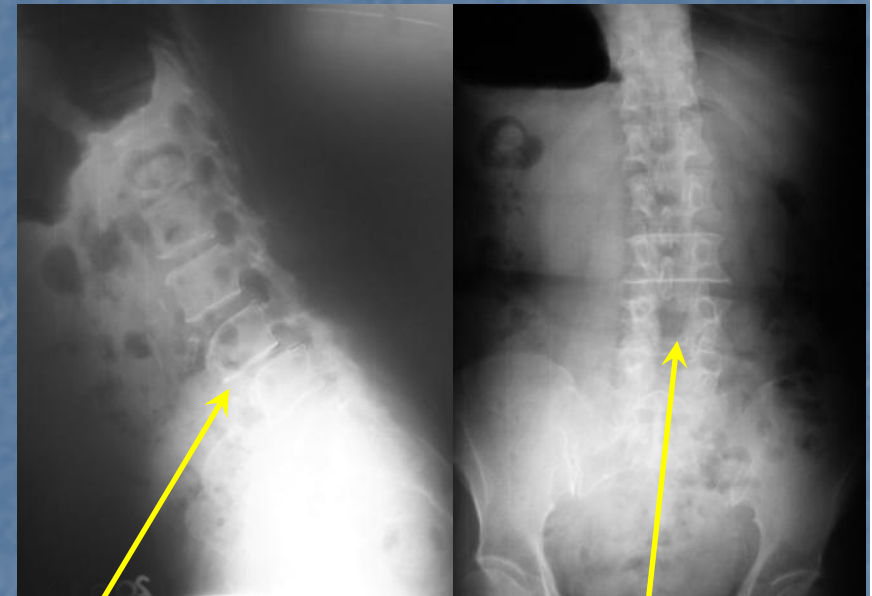
椎板切除術  
laminectomy

## 椎板切除術 (Laminectomy) 示意圖

# 腰椎狹窄症手術

## Lumbar Spinal Stenosis Surgery

- Principle
  - Maximal thecal sac and nerve root decompression and preserves stability
- Preserve stability
  - Postoperative instability
    - Greater than 50% excision of the bilateral facets
    - Unilateral complete facetectomy



spondylolisthesis

laminectomy

術後發生不穩定  
post-laminectomy instability