

Obstetrical Ultrasound Database in Current Practice

邱宗鴻

Tsung-Hong Chiu, M.D.

**Dept. OB/GYN Chang-Gung
Memorial Hospital, Taipei,
TAIWAN**

Database Domain

- **Any measurable figures or numbers**
- **Any personal belongings**
- **Any ROI (region of interest) groupings**
- **Any transmissible images**
- **...etc. enumerate only a few of them**

Potential Uses of Database

(Why it's important to set up a database)

- Used as a reservoir for data storage**
- Retrieval available for review and comparisons**
- Used to edit a formal report after integrating all the related findings or data in database**
- Used to set up so called “normal data” references**
- Used to draw conclusion in regarding the novel techniques or clinical skills applied in related field undergone data collection, critical review, and statistical inferences (data mining and knowledge discovery)**

Tough and stumbling stuff before set-up of infrastructure on OB ultrasound database

- **Not possible in retrieving previous ultrasound data for comparison when performing the follow-up checks**
- **Labor-demanding and labor-exhausted in obtaining formal ultrasound reports, and yet no conclusive report readily available on site, or by request**
- **Inefficient and chaos in taking care of those ultrasound -examined reports**

Nightmares in era before set-up of infrastructure on OB ultrasound database

- **Accumulated pile-up of examined ultrasound results pending for formal reports**
- **Doubling time-consuming in hand-written reports**
- **Only images of interest left without accompanied ultrasound data readily available for review or research statistics**

Computer-Assisted Database Set-up

(Commonly used software)

- **D-base III**
- **Excel**
- **Access**
- **File-Maker**

Prerequisites for Software of Choice

- **Easily to learn and catch up for green-horn**
- **Friendly interface; finger-tip, figure-oriented interaction**
- **Flexible and versatile format in constructing the infrastructures of a comprehensive database**

**FileMaker fit well
into the
aforementioned
criteria**

What items should be covered in comprehensive level II ultrasound examinations

- **Identifiable personal profile data**
- **General review on uterine and surrounding environments including fetus-supporting vital organ**
- **Basic biometric data**
- **Organ system check-up list in sequential ritual way**
- **Special (biometric) measurements**
- **Conclusive remarks and footnotes for postnatal data**

Name.....
Chart Number...
Date of Birth....
Gravida.....
Para.....

Scan Date.....
LMP.....
EDC.....
CEDC.....
Gestational Age...

+

Weeks

Referred by Dr.

Examined by Dr.

Indication 1

Indication 2

OVERVIEW

- 1 Number of fetus _____
- 2 Fetal heart beats _____
- 3 Presentation _____
- 4 Placental localization _____
- 5 Placental thickness _____ cm
- 6 Placental findings _____
- 7 Placental invasiveness adherence _____
- 8 Placental grading _____
- 9 Umbilical cord _____
- 10 Amniotic fluid _____
- 11 Biophysical items _____
- 12 Hydronic changes _____
- 13 Myoma _____
- 14 Adnexal mass _____

FETAL BIOMETRY

1 BPD = _____ cm _____ weeks BPD size _____
2 HC = _____ cm _____ weeks HC size _____
3 AC = _____ cm _____ weeks AC size _____
4 FL = _____ cm _____ weeks FL size _____
5 EFBW = _____ gm _____ weeks EFBW size _____
6 Fetal growth = _____
7 Specific Measurement Ratio (HC/AC Rratio) = _____

CRANIOFACIAL ASPECT

1 Skull integrity and shape _____
2 Midline echo _____
3 Evolving atrium _____ cm
Evolving prominent atrium _____
4 Ventriculomegaly _____
Ventriculomegaly cortical mantle _____ cm
5 Choroid plexus cyst Present, bilateral _____ cm
6 Cerebellum, transverse diameter _____ cm
Cerebellum _____
7 Cleft lip _____
8 IOD OOD Measurement IOD _____ OOD _____ IOD/OOD= _____
9 Facial profile, 3-D reconstruction _____

CHEST

- 1 Lung _____
- 2 Heart position _____
- 3 Four chamber view _____
- 4 Short axis view _____
- 5 Right ventricular outflow tract _____
- 6 Left ventricular outflow tract _____
- 7 Cardiac measurement CC _____ TC _____ CC/TC= _____

ABDOMEN

- 1 Stomach _____
- 2 Bowel _____
- 3 Liver _____
- 4 Gall bladder _____
- 5 Abdominal wall _____
- 6 Intraabdominal space _____
- 7 Abdomen 3D _____

UROGENITAL ASPECT

- 1 Kidney _____
- 2 Kidney measurement 1 Right KC = _____ KC/AC= _____
- 3 Kidney measurement 1 Left KC = _____ KC/AC= _____
- 4 Kidney measurement 2 Right RPD= _____ KCD = _____ RPD/KCD= _____
- 5 Kidney measurement 2 Left RPD= _____ KCD = _____ RPD/KCD= _____
- 6 Kidney measurement 3 Length _____ Thickness _____
- 7 Evolving prominent renal pelvis _____
- 8 Hydroureter _____
- 9 Bladder _____
- 10 Gender _____
- 11 Hydrocele _____
- 12 Uro3D _____

DOPPLER VELOCIMETRY

1 Umbilical artery	S/D	_____	RI	_____	PI	_____
2 Umbilical artery waveform	_____					
3 Middle cerebral artery	S/D	_____	RI	_____	PI	_____
4 Aorta, abdominal	S/D	_____	RI	_____	PI	_____
5 Umbilical vein	_____					
6 Ductus venosus	_____					

CONCLUSIVE REMARKS

However, the possibility of those defects quoted in patients' informed consent can't be ruled out at all at this time, if solely based on this scan.

Tsung-Hong CHIU M.D.

Name.....
Chart Number...
Date of Birth....
Gravida.....
Para.....

Scan Date..... 2001/10/14
LMP.....
EDC.....
CEDC.....
Gestational Age... 104396 1

Weeks

Referred by Dr. []

Examined by Dr. []

Indication 1 []

Indication 2 []

OVERVIEW

- 1 Number of fetus
- 2 Fetal heart beats
- 3 Presentation
- 4 Placental localization
- 5 Placental thickness
- 6 Placental findings
- 7 Placental invasiveness adherence
- 8 Placental grading
- 9 Umbilical cord
- 10 Amniotic fluid
- 11 Biophysical items
- 12 Hydropic changes
- 13 Myoma
- 14 Adnexal mass

[]
[]
[]
[]
[]

[]

- Normal
- Bulky thickened placenta
- Retroplacental echolucency
- Large round echolucent space
- Dilated intervillous space
- Subchorionic cyst
- Subchorionic hematoma
- Lacunar sign
- Chorioangioma

FETAL BIOMETRY

Advantages in current database

- **It is a personal computer-based database with emphasis on descriptive terms and figures on measurement**
- **Input; storage; processing; output - to complete the paper record work flow sequence all in once at finger tip**

Advantages in current database

- It is crucial to construct back-bone database structure to meet the essence of comprehensiveness; convenience; and flexibility
- Pull-down long-list options selection icon design is an ideal unique way to satisfy the limited layout space with versatile choices which can be edited at one's autonomy

Advantages in current database

- Lay-out format at one's desire
- Speedy retrieval results easily obtained when under appropriate searching strategy given
- Instant simple built-in statistical analysis for reference
- Output data can be easily linked with or input to **SPSS** statistical software

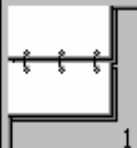
Shortcoming in current ultrasound database

- No ultrasound pictures storage system available and used in combination with descriptive data**
- No digitized combination system used for sending picture-text dataset**
- May need PAC system to make up this shortcoming in the very near future to surf on the future trend tide**

Efforts to push in the coming days

- In terms of OB ultrasound data, to fill in all the blank space in the rest of preceding years with data that had been done in the past 10 more years, with accuracy and continuity
- To set up image database somewhere in the computer and link with discrete searching key on case by case basis
- To apply the database concept to build up interested topics for solid data inferences and conclusions to meet the essence and trend of **Evidence-Based Medicine**

Database



條件:
1

省略(O)

符號(B)

尋找

1 2 3 4 5 6 7 8 9 10 11 12 13 14 15 16 17 18 19 20

Name.....		Scan Date.....	
Chart Number...		LMP.....	
Date of Birth....		EDC.....	
Gravida.....		CEDC.....	
Para.....		Gestational Age...	+ Weeks

Referred by Dr.

Examined by Dr.

Indication 1
Indication 2

OVERVIEW

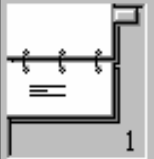
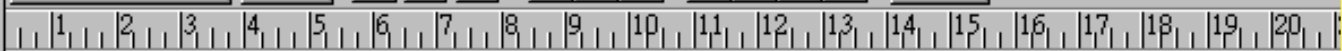1 Number of fetus	Twins
2 Fetal heart beats	
3 Presentation	
4 Placental localization	
5 Placental thickness	cm
6 Placental findings	
7 Placental invasiveness adherence	
8 Placental grading	
9 Umbilical cord	
10 Amniotic fluid	
11 Biophysical items	
12 Hydropic changes	
13 Myoma	
14 Adnexal mass	

FETAL BIOMETRY

1 BPD = cm weeks BPD size

Database

▼ ▼ ▼
B Z U ≡ ≡ ≡
↑ ↑ ↑ ↑
cm ▼



記錄:
5372

找到:
431

未排序

Name.....	WC Lin	Scan Date.....	1989/11/17
Chart Number...	1450319	LMP.....	1989/2/28
Date of Birth.....		EDC.....	1989/12/5
Gravida.....	3	CEDC.....	
Para.....	1	Gestational Age...	37 + 4 Weeks

Referred by Dr. _____ Examined by Dr. TH Chiu

Indication 1 Multiple pregnancy
Indication 2 _____

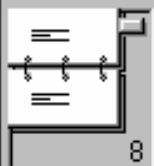OVERVIEW

1 Number of fetus	Twins
2 Fetal heart beats	Present, regular
3 Presentation	_____
4 Placental localization	Anterior
5 Placental thickness	_____ cm
6 Placental findings	Normal
7 Placental invasiveness adherence	Normal
8 Placental grading	III
9 Umbilical cord	2 arteries 1 vein
10 Amniotic fluid	Normal fluid(AFI 8-23)
11 Biophysical items	Breathing + Tone + Movement, present
12 Hydropic changes	None
13 Myoma	None
14 Adnexal mass	None

FETAL BIOMETRY

1 BPD = 9.20 cm 37+ weeks BPD size Appropriate (10-95th percentile)

Ana...



記録:
5372

找到:
176

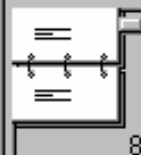未排序

ChartNumber	GA	EFBW	SDa	SDb	RIa	RIb	PIa	PIb	T1	T2
1290926	24	808	2.92		0.66		1.08		1	0
8457715	24	677	4.25		0.76		1.22		1	0
1334759	24	793	2.77		0.64		1.04		1	0
9824412	24	685	4.43		0.77		1.30		1	0
1299447	24	672	3.60		0.72		1.28		1	0
1637060	24	729	4.00		0.75		1.40		1	0
1699207	24	680	4.29		0.77		1.22		1	0
2970840	24	598	4.33		0.77		1.39		1	0
585437	24	789	2.55		0.61		0.84		1	0
1522124	24	688	3.10		0.68		1.09		1	0
8537351	24	783	3.91		0.74		1.43		1	0
1696872	24	910	5.13		0.80		1.44		1	0
2710793	24	801	3.22		0.69		1.09		1	0
2239413	24	709	4.00		0.75		1.21		1	0
8547309	24	840	4.57		0.78		1.38		1	0

AverageSDa 3.63 ± 0.94 AverageSDb 6.90 ± 2.03 AnalysisTotal 175
 AverageRIa 0.71 ± 0.08 AverageRIb 0.87 ± 0.13
 AveragePIa 1.16 ± 0.20 AveragePIb 2.05 ± 1.02

**T1: 0 for Diabetic pregnancy, Multiple pregnancy, Chronic hypertension/ PIH-Preeclampsia or High risk medical disease ; 1 for Non-Diabetic T2: 0 for Appropriate; 1 for Not Appropriate

Ana...

記錄:
5372找到:
176

未排序

ChartNumber	GA	PLthick	Atrium	Cerebe	NNSTh	Tibia	Fibula	Humerus	Ulna	Radius	T1	T2
1982365	24		0.63	2.63		3.89	3.86	4.03	3.89	3.65	1	0
8496359	24		0.80	2.66	0.20	3.68	3.47	3.93	3.40	2.95	1	0
8496492	24		0.63		0.21	3.36	3.15	3.65	3.40	3.01	1	0
1837900	24		0.59	2.70	0.48	3.61	3.58	4.00	3.75	3.43	1	0
1671503	24		0.55	2.70		3.96	3.86	4.00	3.93	3.43	1	0
8504331	24		0.63	2.45		3.86	3.75	4.03	3.71	3.33	1	0
1011861	24		0.63	2.41	0.41	3.65	3.43	3.79	3.65	2.95	1	0
8420794	24		0.66	2.66		3.71	3.71	3.96	3.79	3.51	1	0
1050218	24		0.87	2.66		3.65	3.54	3.71	3.51	3.19	1	0
1451269	24		0.63	3.15		4.21	3.71	4.17	3.61	3.12	1	0
3371511	24		0.55	2.50		3.71	3.68	4.07	3.93	3.43	1	0

AveragePlacenta 2.90 ± 0.67 AnalysisTotal 175

AverageAtrium 0.63 ± 0.06

AverageCerebel 2.62 ± 0.17

AverageNNSTh 0.30 ± 0.13

AverageTibia 3.78 ± 0.23

AverageFibula 3.69 ± 0.22

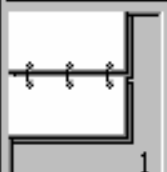
AverageHumerus 3.91 ± 0.38

AverageUlna 3.74 ± 0.21

AverageRadius 3.30 ± 0.37

**T1: 0 for Diabetic pregnancy, Multiple pregnancy, Chronic hypertension/ PIH-Preeclampsia or High risk medical disease ; 1 for Non-Diabetic T2: 0 for Appropriate; 1 for Not Appropriate

Database



條件:

1

 省略(O)

符號(B)

尋找

1 2 3 4 5 6 7 8 9 10 11 12 13 14 15 16 17 18 19 20

UROGENITAL ASPECT

1 Kidney

Polycystic

2 Kidney measurement 1 Right

KC =

KC/AC=

3 Kidney measurement 1 Left

KC =

KC/AC=

4 Kidney measurement 2 Right

RPD=

KCD =

RPD/KCD=

5 Kidney measurement 2 Left

RPD=

KCD =

RPD/KCD=

6 Kidney measurement 3

Length

Thickness

7 Evolving prominent renal pelvis

8 Hydroureter

9 Bladder

10 Gender

11 Hydrocele

12 Uro3D

DOPPLER VELOCIMETRY

1 Umbilical artery

S/D

RI

PI

2 Umbilical artery waveform

3 Middle cerebral artery

S/D

RI

PI

4 Aorta,abdominal

S/D

RI

PI

5 Umbilical vein

6 Ductus venosus

CONCLUSIVE REMARKS

記錄:
5372找到:
4

未排序

UROGENITAL ASPECT

1 Kidney	Polycystic		
2 Kidney measurement 1 Right	KC = 14.71	KC/AC= 0.377	
3 Kidney measurement 1 Left	KC = 13.6	KC/AC= 0.349	
4 Kidney measurement 2 Right	RPD= 0.21	KCD = 2.91	RPD/KCD= 0.072
5 Kidney measurement 2 Left	RPD= 0.42	KCD = 4.16	RPD/KCD= 0.101
6 Kidney measurement 3	Length 8.56	Thickness 4.46	
7 Evolving prominent renal pelvis	None		
8 Hydroureter	None		
9 Bladder	Present		
10 Gender	Female		
11 Hydrocele	None		
12 Uro3D	Not done		

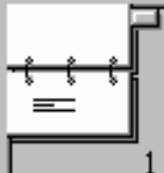
DOPPLER VELOCIMETRY

1 Umbilical artery	S/D 4.5	RI 0.78	PI 1.5
2 Umbilical artery waveform	Increased flow impedance		
3 Middle cerebral artery	S/D	RI	PI
4 Aorta, abdominal	S/D	RI	PI
5 Umbilical vein	Present		
6 Ductus venosus	Present		

CONCLUSIVE REMARKS

Through the available sectional views, the scanning revealed the fetus in accelerated growth and associated with bilateral polycystic dysplastic kidney disease. Gastric bubble was not clearly shown. Follow up scan is advised 2 weeks later.

Ana...



記錄:
5372

找到:
119

未排序

ChartNumber	GA	IOD/OOD	CC	KCR	KC/AC	RPD/KCD	KCL	KC/AC	RPD/KCD	Kidney
9803023	33	.28214	0.50				6.97	0.22	0.20	
8422182	33	.25314	0.50	8.52	0.27	0.18	7.49	0.24	0.14	
1850535	33	.23339	0.51	6.41	0.21	0.11	5.61	0.18	0.15	
8523890	33	.27531	0.49	7.99	0.24	0.15	7.67	0.23	0.21	
9997137	33	.29856	0.44	8.41	0.25	0.11				
9734267	33	.28109		8.80	0.28	0.13	8.45	0.27	0.13	
10085181	33	.24904	0.53				7.10	0.23	0.24	
9908857	33	.28980		7.71	0.24	0.11	6.83	0.21	0.15	
2845791	33			7.86	0.25	0.26	7.45	0.24	0.17	

AverageInterocu	0.28	±	0.04
AverageCTR	0.38	±	0.23
AverageKCRt	7.94	±	0.84
AverageKC/AC	0.25	±	0.02
AverageRPD/KCD	0.19	±	0.07
AverageKCLt	7.61	±	0.70
AverageKC/AC	0.24	±	0.02
AverageRPD/KCD	0.20	±	0.07
AverageKidney	2.64	±	0.32
AverageKidney	3.55	±	1.35

Analysis Total 118

UROGENITAL ASPECT			
1 Kidney	Polycystic		
2 Kidney measurement 1 Right	KC = 14.71	KC/AC = 0.377	
3 Kidney measurement 1 Left	KC = 13.6	KC/AC = 0.349	
4 Kidney measurement 2 Right	RPD = 0.21	KCD = 2.91	RPD/KCD = 0.072
5 Kidney measurement 2 Left	RPD = 0.42	KCD = 4.16	RPD/KCD = 0.101
6 Kidney measurement 3	Length 8.56	Thickness 4.46	

Para.....

Gestational Age... 27 + 3

Weeks

Referred by Dr.

Examined by Dr. TH Chiu

Indication 1 Pregnancy loss, repeated

Indication 2 Preterm labor

記錄:
5372找到:
312

未排序

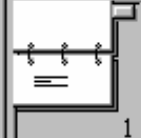
OVERVIEW

1 Number of fetus	Singleton
2 Fetal heart beats	Present, regular
3 Presentation	
4 Placental localization	Anterior
5 Placental thickness	cm
6 Placental findings	Normal
7 Placental invasiveness adherence	Normal
8 Placental grading	I
9 Umbilical cord	2 arteries 1 vein
10 Amniotic fluid	Oligohydramnios(AFI < 8)
11 Biophysical items	Tone + Movement, present
12 Hydropic changes	None
13 Myoma	None
14 Adnexal mass	None

FETAL BIOMETRY

1 BPD	=	6.20	cm	24+	weeks	BPD size	Restricted (< 10th percentile)
2 HC	=	22.70	cm	24+	weeks	HC size	Restricted (< 10th percentile)
3 AC	=	18.20	cm	23+	weeks	AC size	Restricted (< 10th percentile)
4 FL	=	4.50	cm	26+	weeks	FL size	Appropriate (10-95th percentile)
5 EFBW	=	787	g		weeks	EFBW size	Restricted (< 5th percentile)
6 Fetal growth	=						Restricted (< 10th percentile)

Ana...



記錄：
5335

找到：
151

未排序

ChartNumber	GA	PLthick	Atrium	Cerebe	NNSTh	Tibia	Fibula	Humerus	Ulna	Radius	T1	T2
479247	26										1	0
2249822	26					3.70					1	0
1345277	26										1	0
779061	26										1	0
1454929	26					3.80		4.00			1	0
424500	26										1	0
1471800	26			3.20							1	0
843892	26										1	0
1479166	26										1	0
841235	26										1	0
1276909	26										1	0
1497009	26										1	0

AveragePlacenta	3.05	± 0.73	AnalysisTotal	151
AverageAtrium	0.65	± 0.14		
AverageCerebel	2.95	± 0.19		
AverageNNSTh	0.26	± 0.08		
AverageTibia	4.18	± 0.23		
AverageFibula	4.07	± 0.21		
AverageHumerus	4.31	± 0.25		
AverageUlna	4.10	± 0.25		
AverageRadius	8.03	± 41.16		

A careless error should be pursued with when obviously deviated statistic number was found

**T1: 0 for Diabetic pregnancy, Multiple pregnancy, Chronic hypertension/ PIH-Preeclampsia or High risk medical disease ; 1 for Non-Diabetic T2: 0 for Appropriate; 1 for Not Appropriate

Microsoft Excel - F

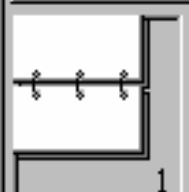
檔案(E) 編輯(E) 檢視

新細明體 12

B1

	A	B
72	26	3.86
73	26	3.87
74	26	3.89
75	26	3.89
76	26	3.89
77	26	3.89
78	26	3.9
79	26	3.91
80	26	3.93
81	26	3.93
82	26	3.99
83	26	3.99
84	26	4.07
85	26	4.14
86	26	4.23
87	26	4.26
88	26	4.71
89	26	392

Database



條件:

1

省略(O)

符號(B)

尋找

1 2 3 4 5 6 7 8 9 10 11 12 13 14 15 16 17 18 19 20 21

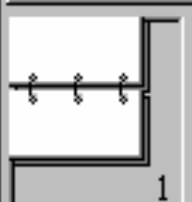
_____ cm

6 Cerebellum,transverse diameter _____ cm
 Cerebellum _____ CerebellumAC ratio
 7 Cleft lip _____
 8 IOD OOD Measurement IOD _____ OOD _____ IOD/OOD= _____
 9 Facial profile,3-D reconstruction _____

SPINE and SKELETAL ASPECT

1 Neck nuchal skinfold thickness _____ cm
 2 Neck mass _____
 3 Spine _____
 4 Lower extremities measurement (a) Tibia _____ cm (b) Fibula _____ cm
 5 Lower long bones _____
 6 Foot _____
 7 Toes _____
 8 Upper extremities measurement (a) Humerus _____ cm (b) Ulna _____ cm (c) Radius 392 _____ cm
 9 Upper long bones _____
 10 Hand _____
 11 Fingers _____
 12 Fingers Toes 3D _____

Database



記錄:
5335

找到:
1

未排序

1 2 3 4 5 6 7 8 9 10 11 12 13 14 15 16 17 18 19 20 21

None cm

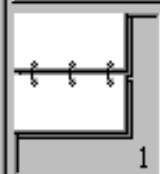
6 Cerebellum,transverse diameter	2.74	cm
Cerebellum	Appropriate	CerebellumAC ratio 0.1165
7 Cleft lip	None	
8 IOD OOD Measurement	IOD 1.41	OOD 4.47 IOD/OOD= 0.315
9 Facial profile,3-D reconstruction	Not done	

SPINE and SKELETAL ASPECT

1 Neck nuchal skinfold thickness	0.25	cm
2 Neck mass	None	
3 Spine	Parallel arrangement	
4 Lower extremities measurement	(a) Tibia 4.2 cm (b) Fibula 4.18	cm
5 Lower long bones	Unilateral,not confirmed	
6 Foot	Present	
7 Toes	Unilateral,not confirmed	
8 Upper extremities measurement	(a) Humerus 4.22 cm (b) Ulna 4.05 cm (c) Radius 3.92	cm
9 Upper long bones	Unilateral,not confirmed	
10 Hand	Unilateral,not confirmed	
11 Fingers	Unobtainable	
12 Fingers Toes 3D	Not done	

Database [v] [v] [B] [Z] [U] [≡] [≡] [≡] [↑] [↑] [↑] [↑] [cm] [v]

1 2 3 4 5 6 7 8 9 10 11 12 13 14 15 16 17 18 19 20 21



記錄:
5335

找到:
1

未排序

Name.....	CW Hu	Scan Date.....	2001/5/29
Chart Number...	9832106	LMP.....	2000/11/24
Date of Birth.....	1973/6/4	EDC.....	2001/8/31
Gravida.....	1	CEDC.....	
Para.....	0	Gestational Age...	26 + 5 Weeks

Referred by Dr. TH Chiu Examined by Dr. TH Chiu

- Indication 1 Multiple pregnancy
- Indication 2 Hx of unc twin

OVERVIEW

1 Number of fetus	Twins
2 Fetal heart beats	Present, regular
3 Presentation	Vertex
4 Placental localization	Posterolateral,left
5 Placental thickness	3.49 cm
6 Placental findings	Twin peg present
7 Placental invasiveness adherence	Normal
8 Placental grading	II
9 Umbilical cord	2 arteries 1 vein
10 Amniotic fluid	Normal fluid(AFI 8-23)
11 Biophysical items	Breathing + Tone + Movement, present
12 Hydropic changes	None
13 Myoma	None
14 Adnexal mass	None

Ana... ▾



記録:
5335

找到:
151

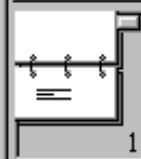
未排序

ChartNumber	GA	PLthick	Atrium	Cerebe	NNSTh	Tibia	Fibula	Humerus	Ulna	Radius	T1	T2
479247	26										1	0
2249822	26					3.70					1	0
1345277	26										1	0
779061	26										1	0
1454929	26					3.80		4.00			1	0
424500	26										1	0
1471800	26				3.20						1	0
843892	26										1	0
1479166	26										1	0
841235	26										1	0
1276909	26										1	0
1497009	26										1	0

AveragePlacenta	3.05	±	0.73	AnalysisTotal	151
AverageAtrium	0.65	±	0.14		
AverageCerebel	2.95	±	0.19		
AverageNNSTh	0.26	±	0.08		
AverageTibia	4.18	±	0.23		
AverageFibula	4.07	±	0.21		
AverageHumerus	4.31	±	0.25		
AverageUlna	4.10	±	0.25		
AverageRadius	3.67	±	0.24		

**T1: 0 for Diabetic pregnancy, Multiple pregnancy, Chronic hypertension/ PIH-Preeclampsia or High risk medical disease; 1 for Not Diabetic; T2: 0 for Assymetric; 1 for Not Assymetric

Ana... ▾



記錄：
5335

找到：
290

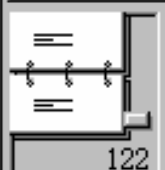
未排序

ChartNumber	GA	PLthick	Atrium	Cerebe	NNSTh	Tibia	Fibula	Humerus	Ulna	Radius	T1	T2
1193305	29										1	1
455127	29										1	1
357307	29										1	1
1417767	29										1	0
1316685	29					4.40					1	0
449784	29					4.50					1	1
1427143	29										1	1
1392181	29										1	0
1239168	29										1	1
340209	29							4.50			1	0
1397171	29					4.20					0	1
378409	29					4.10					1	0

AveragePlacenta	3.39	±	0.70	AnalysisTotal	289
AverageAtrium	0.66	±	0.14		
AverageCerebel	3.44	±	0.23		
AverageNNSTh	0.25	±	0.07		
AverageTibia	8.14	±	37.97		
AverageFibula	4.63	±	0.25		
AverageHumerus	4.87	±	0.28		
AverageUlna	4.58	±	0.25		
AverageRadius	4.13	±	0.29		

**T1: 0 for Diabetic pregnancy, Multiple pregnancy, Chronic hypertension/ PIH-Preeclampsia or High risk medical disease ; 1 for Non-Diabetic T2: 0 for Appropriate; 1 for Not Appropriate

Database



記錄:
290

找到:
126

未排序

7 Specific Measurement Ratio (HC/AC Rratio) = _____

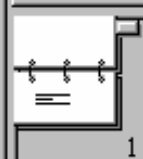
CRANIOFACIAL ASPECT

- 1 Skull integrity and shape _____
 - 2 Midline echo _____
 - 3 Evolving atrium _____ cm
 - Evolving prominent atrium _____
 - 4 Ventriculomegaly _____
 - Ventriculomegaly cortical mantle _____ cm
 - 5 Choroid plexus cyst _____ cm
 - 6 Cerebellum,transverse diameter _____ cm
 - Cerebellum _____ CerebellumAC ratio
 - 7 Cleft lip _____
 - 8 IOD OOD Measurement IOD _____ OOD _____ IOD/OOD= _____
 - 9 Facial profile,3-D reconstruction _____
-

SPINE and SKELETAL ASPECT

- 1 Neck nuchal skinfold thickness _____ cm
- 2 Neck mass _____
- 3 Spine _____
- 4 Lower extremities measurement (a) Tibia 431 _____ cm (b) Fibula _____ cm
- 5 Lower long bones _____
- 6 Foot _____
- 7 Toes _____

Ana...



記錄:
5335

找到:
258

未排序

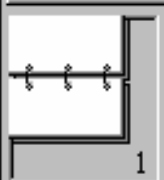
ChartNumber	GA	PLthick	Atrium	Cerebe	NNSTh	Tibia	Fibula	Humerus	Ulna	Radius	T1	T2
414745	32					4.90					1	1
1398472	32					5.00					1	0
1395439	32							5.30			1	0
1384101	32					4.70					1	0
735237	32							5.10			1	0
1239168	32					4.20					1	0
1383300	32										1	0
834591	32										1	0
1080407	32					4.70		4.80			1	0
1454406	32					4.80		5.00			1	0
280753	32					5.40		5.10			1	0
1421894	32										1	1

AveragePlacenta	3.94	±	0.76	AnalysisTotal	256
AverageAtrium	0.65	±	0.07		
AverageCerebel	3.95	±	0.36		
AverageNNSTh	0.26	±	0.09		
AverageTibia	5.22	±	0.37		
AverageFibula	5.08	±	0.35		
AverageHumerus	5.26	±	0.38		
AverageUlna	4.99	±	0.34		
AverageRadius	16.26	±	75.21		

**T1: 0 for Diabetic pregnancy, Multiple pregnancy, Chronic hypertension/ PIH-Preeclampsia or High risk medical disease ; 1 for Non-Diabetic T2: 0 for Appropriate; 1 for Not Appropriate

Database

1 2 3 4 5 6 7 8 9 10 11 12 13 14 15 16 17 18 19 20 21 22



條件:
1

省略(O)

符號(B)

尋找

10 Anatomical items _____

11 Biophysical items _____

12 Hydroptic changes _____

13 Myoma _____

14 Adnexal mass _____

FETAL BIOMETRY

1 BPD = _____ cm _____ weeks BPD size _____

2 HC = _____ cm _____ weeks HC size _____

3 AC = _____ cm _____ weeks AC size _____

4 FL = _____ cm _____ weeks FL size _____

5 EFBW = _____ gm _____ weeks

6 Fetal growth = _____

7 Specific Measurement Ratio (HC/AC Rrat: _____

CRANIOFACIAL ASPECT

1 Skull integrity and shape _____

2 Midline echo _____

3 Evolving atrium _____ cm

 Evolving prominent atrium _____

4 Ventriculomegaly Hydrocephalus, unspecified _____

 Ventriculomegaly cortical mantle _____ cm

5 Choroid plexus cyst _____ cm

6 Cerebellum, transverse diameter _____ cm

 Cerebellum _____ CerebellumAC ratio _____

7 Cleft lip _____

8 IOD OOD Measurement IOD _____ OOD _____ IOD/OOD= _____

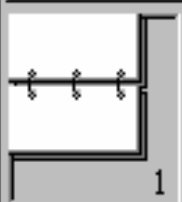
9 Facial profile, 3-D reconstruction _____

FileMaker Pro [X]

沒有任何一筆記錄符合此條件。

[修改尋找(M)] [取消]

Database



條件:
1

省略(O)

符號(B)

尋找

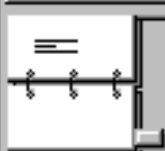
Rich text editor toolbar with buttons for Bold (B), Italic (I), Underline (U), Bulleted List, Numbered List, Indent, and Outdent. A unit dropdown menu is set to 'cm'. Below the toolbar is a ruler with markings from 1 to 21.

3 AC =	<input type="text"/>	cm	<input type="text"/>	weeks	AC size	<input type="text"/>
4 FL =	<input type="text"/>	cm	<input type="text"/>	weeks	FL size	<input type="text"/>
5 EFBW =	<input type="text"/>	gm	<input type="text"/>	weeks	EFBW size	<input type="text"/>
6 Fetal growth =	<input type="text"/>					
7 Specific Measurement Ratio (HC/AC Rratio) =	<input type="text"/>					

CRANIOFACIAL ASPECT

1 Skull integrity and shape	<input type="text"/>				
2 Midline echo	<input type="text"/>				
3 Evolving atrium	<input type="text"/>				cm
Evolving prominent atrium	<input type="text"/>				
4 Ventriculomegaly	Present, unspecified laterality				
Ventriculomegaly cortical mantle	<input type="text"/>				cm
5 Choroid plexus cyst	<input type="text"/>				<input type="text"/> cm
6 Cerebellum, transverse diameter	<input type="text"/>				cm
Cerebellum	<input type="text"/>				CerebellumAC ratio <input type="text"/>
7 Cleft lip	<input type="text"/>				
8 IOD OOD Measurement	IOD	<input type="text"/>	OOD	<input type="text"/>	IOD/OOD= <input type="text"/>
9 Facial profile, 3-D reconstruction	<input type="text"/>				

Database



29

記錄:
5333找到:
29

未排序

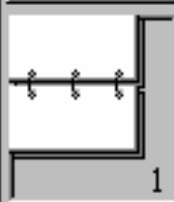
1	2	3	4	5	6	7	8	9	10	11	12	13	14	15	16	17	18	19	20	21	22
---	---	---	---	---	---	---	---	---	----	----	----	----	----	----	----	----	----	----	----	----	----

3 AC	=	24.36	cm	28+	weeks	AC size	Appropriate (10-95th percentile)
4 FL	=	5.62	cm	31+	weeks	FL size	Accelerated (> 95th percentile)
5 EFBW	=	1384	gm		weeks	EFBW size	Appropriate (10-95th percentile)
6 Fetal growth	=	Appropriate (10-95th percentile)					
7 Specific Measurement Ratio (HC/AC Rratio)	=	1.14					

CRANIOFACIAL ASPECT

1 Skull integrity and shape	Intact normal		
2 Midline echo	Present		
3 Evolving atrium	1.23		cm
Evolving prominent atrium	Present, unspecified laterality		
4 Ventriculomegaly	Present, unspecified laterality		
Ventriculomegaly cortical mantle			cm
5 Choroid plexus cyst	None		cm
6 Cerebellum, transverse diameter	3.76		cm
Cerebellum	Accelerated	CerebellumAC ratio	0.1544
7 Cleft lip	None		
8 IOD OOD Measurement	IOD	OOD	IOD/OOD=
9 Facial profile, 3-D reconstruction	Not done		

Database



條件:
1

省略(O)

符號(B)

尋找

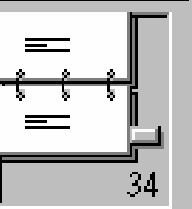
1 2 3 4 5 6 7 8 9 10 11 12 13 14 15 16 17 18 19 20 21

B **I** **U** **≡** **≡** **≡** **↑** **↑** **↑** **↑** **cm**

CRANIOFACIAL ASPECT

- 1 Skull integrity and shape _____
- 2 Midline echo _____
- 3 Evolving atrium _____ cm
- Evolving prominent atrium _____
- 4 Ventriculomegaly Pres _____
- Ventriculomegaly cortical mantle _____ cm
- 5 Choroid plexus cyst _____ cm
- 6 Cerebellum,transverse diameter _____ cm
- Cerebellum _____ CerebellumAC ratio
- 7 Cleft lip _____
- 8 IOD OOD Measurement IOD _____ OOD _____ IOD/OOD= _____
- 9 Facial profile,3-D reconstruction _____

Database



記錄:
5333

找到:
36

未排序

Rich text editor toolbar with buttons for Bold (B), Italic (I), Underline (U), Bulleted List, Numbered List, Indent, and Outdent, followed by a unit dropdown menu set to 'cm'.



CRANIOFACIAL ASPECT

1 Skull integrity and shape	Intact normal		
2 Midline echo	Present		
3 Evolving atrium	1.23	cm	
Evolving prominent atrium	Present, unspecified laterality		
4 Ventriculomegaly	Present, unspecified laterality		
Ventriculomegaly cortical mantle		cm	
5 Choroid plexus cyst	None		cm
6 Cerebellum, transverse diameter	3.76	cm	
Cerebellum	Accelerated		CerebellumAC ratio 0.1544
7 Cleft lip	None		
8 IOD OOD Measurement	IOD _____	OOD _____	IOD/OOD= _____
9 Facial profile, 3-D reconstruction	Not done		

Name..... SH Huang
Chart Number... 1796182
Date of Birth.... 1967/8/26
Gravida..... 2
Para..... 1

Scan Date..... 2002/1/24
LMP.....
EDC.....
CEDC..... 2002/5/26
Gestational Age... 22 + 5 Weeks

Referred by Dr. TT Hsieh

Examined by Dr. TH Chiu

Indication 1 Advanced maternal age

Indication 2 No Amniocentesis

Remarks “no amniocentesis” for references

Name..... WY Wu
Chart Number... 555868
Date of Birth.... 1967/7/12
Gravida..... 1
Para..... 0

Scan Date..... 2002/1/17
LMP..... 2001/6/1
EDC..... 2002/3/8
CEDC.....
Gestational Age... 32 + 6 Weeks

Referred by Dr. LM Lo

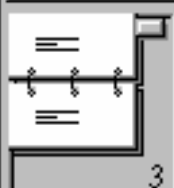
Examined by Dr. TH Chiu

Indication 1 Fetal problem, malformation suspected Inc.Atrium

Indication 2 Follow up

Remarks “follow up” for single case with repeated exams

Database

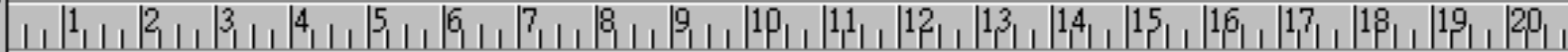

記錄:
5332

找到:
244

未排序

Database
▼
▼
B
I
U
≡
≡
≡
↑
↑
↑
↑
cm
▼



9 Bladder	Present
10 Gender	Female
11 Hydrocele	None
12 Uro3D	Not done

DOPPLER VELOCIMETRY

1 Umbilical artery	S/D	RI	PI
2 Umbilical artery waveform			
3 Middle cerebral artery	S/D	RI	PI
4 Aorta,abdominal	S/D	RI	PI
5 Umbilical vein			
6 Ductus venosus			

CONCLUSIVE REMARKS

76/3/10 39 weeks SD female 3200gm
CVS 46, XX

However, the possibility of those defects quoted in patients' informed consent can't be ruled out at all at this time, if solely based on this scan.

Tsung-Hong CHIU M.D.

Preauricular skin tags on Rt ear

Conclusion: from database to clinical applications

- **Integrate all observed or measurable items which may form clinical implications after data collection, processing, and inference.**
- **Retrieve the data and scrutinize its validity in different facets to achieve absolute accuracy.**
- **Understand and survive in traps and tricks.**

Conclusions - *Potential uses on OB ultrasound database*

- **Establish normal biometric data at each specific gestational age for reference**
- **As for ultrasound examination report per se, it can be retrieved for retrospective comparative study; listed or printed for clinical use**
- **Accumulate fetal biometric data or abnormal ultrasound findings for prospective clinical study**